



ICT - A rapid, innovative but simple technique for malaria diagnosis

Hetal K. Panchal^{1*} and Pratibha B. Desai²

1, Dolat Usha Institute of Applied Sciences, Valsad, Veer Narmad South Gujarat University, Surat, (Gujarat) - India

2, Shree RamKrishna Institute of Computer Education and Applied Sciences, Veer Narmad South Gujarat University, Surat, (Gujarat) – India

Abstract

Early, proper and accurate diagnosis plays an important role in case of malaria. Usually malarial diagnosis is done using clinical criteria and/or microscopy. Immunochromatographic tests (ICTs) are now a days widely available and recognized as an alternative method for diagnosis of the malaria. In this study we performed microscopy i. e. Field's stain and ICT with the help of ParaHIT Total for 897 samples, collected from various clinical laboratories of Valsad district, Gujarat, India. Among them with microscopy 203 but with ICT 198 samples were found malaria positive. In case of microscopy *Plasmodium vivax* (137), *P. falciparum* (65) and in (01) case mix infection was found where as by ICT 65 samples were recognized as *P. falciparum*, and 133 found positive as *P. vivax*. Results of ICT were immediately informed to physicians/patients for faster treatment. Unlike microscopy it is very easy to perform even a layman-nontechnical person can perform it. Even the specificity and sensitivity of dipstick test was found high. Simplicity, easiness and quick results were three important characteristics of ICT which will make it method of choice even in areas where adequate healthcare facilities are not properly available.

Key-Words: Malaria, Malaria diagnosis, ICT, Microscopy.

Introduction

Every year 500 million people infected with malaria and 2.5 million people died of it¹. Malaria has been a major parasitic, communicable tropical disease transmitted by the *Anopheles* mosquito and caused by four Plasmodium species namely *Plasmodium vivax*, *P. falciparum*, *P. ovale*, *P. malariae*. Among them *P. vivax*, *P. falciparum* are common in India. The re-emergence of malaria has been reported in several countries such as India, Peru, China and Korea^{2, 3}. It has become a serious health problem in these countries. Valsad district of Gujarat state, India is considered as one of the malaria endemic area⁴. Even in rural areas proper adequate healthcare facilities are not properly available in India at some places.

Early diagnosis and vital treatment are keys to address morbidity and mortality due to malaria⁵⁻⁷. Microscopy remains the gold standard for detection of malaria as it can provide information on both the species of parasite and density of parasite^{8, 9}.

* Corresponding Author

E-Mail: hetal.mistry1982@gmail.com
Mob.: +919327351081

Fundamental to improving the care of patients infected with malaria is proper and accurate diagnosis in order to prevent excess morbidity and mortality while avoiding unnecessary use of antimalarial agents and minimizing the spread of resistance to antimalarial drugs. Diagnostic strategies need to be effective not only in resource limited areas where malaria has a substantial burden on society but also in developed countries where expertise in the diagnosis of malaria is frequently lacking^{10, 11}.

Immunochromatographic Tests (ICTs) are now a days widely available as a modern technique of malaria rapid diagnostic, which is a faster method, easy to perform, does not require any costlier equipment and give results within 15 to 30 minutes^{12, 13}. Malaria antigens currently targeted by ICTs are Histidine-Rich-Protein II (HRP II)¹⁴ for *P. falciparum*, parasite Lactate Dehydrogenase (pLDH)¹⁵ and adolase¹⁶ for other species. It has been estimated that 16 million ICTs were delivered in 2006 all over the world, of which 10.8 million were in Africa and 2.8 million in India¹⁷.

We performed microscopic diagnosis from Field stained blood smears prepared from all 897 samples and they were further also diagnosed by ParaHIT Total,

which can differentiate both *Plasmodium falciparum* and *Plasmodium vivax*.

Material and methods

The fresh flowers of *Rakta Karpasa* (*Gossypium*) Various blood samples were collected from 897 patients showing symptoms of malaria in between July 2010 to November 2010 at various clinical laboratories and hospitals of Valsad district, Gujarat, India. All samples were immediately tested with ICT ParaHIT Total. The kits were obtained from Span Diagnostics, Surat, India. The kits were stored at room temperature until use. The dipstick of ICT is a nitrocellulose membrane coated with anti HRP II antibodies, anti pLDH/adolase and anti mouse antisera as 3 parallel non visible lines. 8 µl of blood sample was collected from patient's finger prick in heparinized capillary provided along with the kit. Blood samples were blotted on the sample pad just below the arrow on the dipstick. The dipstick with the arrow pointing downwards was dipped in 4 drops of reaction buffer taken in a clean test tubes provided along with the kit. Results were recorded at the end of 15 minutes and maximum within 30 minutes and immediately given to the patients.

Thick and thin smears were prepared on slide at the same time. They were stained with Field's stain B and A for 5 and 12 seconds respectively¹⁸. Thick smears were used to confirm malaria and to count parasites/µl. Smears were considered negative, if no parasites were observed in 200 consecutive fields of thick smear in oil immersion objective. Parasites were counted against 200 to 500 leucocytes. For the parasite estimation it was assumed that 8000 leucocytes present in 1 µl of blood^{19,20}. Thin smears were used to identify and differentiate parasites.

Results and Discussion

203 of 897 patients had malaria infection according to Microscopic diagnosis of blood film examination. 137 had *P. vivax*, 65 had *P. falciparum* and 01 had mix infection with *P. vivax* and *P. falciparum*. 694 cases were diagnosed negative (Table I, Table II). Figures showing observation of ICT and microscopy are shown below as Fig. 1 and Fig. 2 respectively.

Out of 897 samples 198 were diagnosed positive, 65 as *P. falciparum* and 133 as *P. vivax*, where as 699 samples were diagnosed negative by ParaHIT Total RDT (Table I, Table II). The sensitivity and specificity of the test found was also high about 92.12% and 98.41% respectively.

Microscopy at least needs nearly an hour and laborious procedure and involve tough microscopic observation. Skilled professional is required to observe the same.

Sometime when parasitemia is very low even a keen observation may lead to false negative diagnosis. It is also not easy to differentiate different *Plasmodium* species without ample experience. In internal rural areas where skilled malaria detecting professionals are not available diagnosis may take longer time and lead to improper diagnosis of malaria and there by treatment which some time even lead to death. In this situation alternatively we suggest ICT as optional method to diagnose malaria. In our study we were able to perform ICT within couple of minutes. It was easy to perform that even a new lab technician can also perform it.

We were able to give results soon within 5 minutes but as per manufacturers instruction we gave results to patients after 15 minutes so that their treatment can appropriately get start. Even the ICT was able to differentiate between *P. falciparum* and *P. vivax* and even a layman can perform and interpret the results. The sensitivity and specificity of the test found was also high. Compared with microscopic diagnosis, the ParaHIT Total ICT was found false positive/negative in some patients. This may be due to persistent antigenemia following treatment of malaria with recent history of malaria, because in some cases antigenemia may remain positive 3-28 days after disappearance of circulating parasites²¹. False positive results may be due to rheumatoid factor, hepatitis etc²². This may be due to a non specific reaction of rheumatoid factor, hepatitis antigens with coated antibodies.

Our study was valuable because the sample size was quite large about 897 samples to access the acceptability of ICT. It suggests ICT as a better replacement of microscopy in diagnosis of malaria. Malaria is a life threatening infection influences most developed as well as under developed countries of the world with regions of the world lacking basic health infrastructure. High burden of disease, emerging antimalarial drug resistance and broad implementation of ACT are placing greater emphasis on rapid and accurate diagnosis of patients infected with malaria. There is a difficulty in performing microscopy so, alternative diagnosis method is required. The possible answer we found is ICT which no more require any skilled personnel like microscopy and is a faster cheaper and reliable as we found it. Even any lay man can perform it after giving him a simple understanding. A highly effective ICT could avert over 100,000 malaria related deaths and about 400 million unnecessary treatments²³. ICT do not eliminate the need of microscopy until a new gold standard is developed, but Malaria ICTs are ushering in a new era of diagnosis to improve the overall global health care system.

Acknowledgements

The authors wish to thank to staff of all clinical laboratories of Valsad district, who gave their valuable support. The authors also wish to thank management and staff of Shree RamKrishna Institute of Computer Education and Applied Sciences, Surat; Dolat Usha Institute of Applied Sciences, Valsad.

References

- Nussenzweig R. S. and Zavala F. (1997). A malaria vaccine based on a sporozoite antigen. *N. Engl. J. Med.* **336**: 128-130.
- Sharma P. (1996). Re-emergence of malaria in India. *Indian J. Med. Parasitol.* **103**: 26-45.
- Chadee D. D., Maitre A. L. and Tillukdharry C. C. (1992). An outbreak of *Plasmodium vivax* malaria in Trinidad. *W. I. Ann. Trop. Med. Parasitol.* **45**: 583-590.
- Srivastava H. C. and Yadav R. S. (2000). Malaria outbreaks in tribal area of Gujarat state, India.
- Nabarro D. N. and Taylor E. M. (1998). The Roll Back Malaria Campaign. *Science.* **280 (5372)**: 2067-2068.
- World Health Organization (1993). A global strategy for malaria control, Geneva, World Health Organization.
- World Health Organization (2000). Roll Back Malaria-A global partnership, Geneva, World Health Organization.
- Murray C. K., Gasser R. A. Jr., Magill A. J. and Miller R. S. (2008). Update on rapid diagnostic testing for malaria. *Clinical Microbiology Reviews.* **21, no. 1**: 97-110.
- Barnwell J. W., Causer L. and Bloland P. B. (2003). Strategies for improved diagnosis for malaria, including rapid diagnosis.
- Bell D., Wongsrichanalai C. and Barnwell J. N. (2006). Ensuring quality and access for malaria diagnosis: how can it be achieved? *Nature Reviews Microbiology.* **4, no. 9**: 682-695.
- Reyburn H., Mbakilwa H. and Mwangi R. (2007). Rapid diagnostic tests compared with malaria microscopy for guiding outpatients' treatment of febrile illness in Tanzania: randomized trial. *British Medical Journal.* **334, no. 7590**: 403.
- Peyron F., Martet G. and Vigier J. P. (1994). Dipstick antigen capture assay for malaria detection. *Lancet.* **343(8911)**: 1502-1503.
- Singh N., Valecha M. and Sharma V. P. (1997). Malaria diagnosis by field workers using an immunochromatographic test. *Transactions of the Royal Society of Tropical Medicine and Hygiene.* **91(4)**: 396-397.
- Rock E. P., Marsh K., Saul A. J., Wellems T. E., Taylor D. W., Maloy W. L. and Howard R. J. (1987). Comparative analysis of the *Plasmodium falciparum* histidine-rich-proteins HRP I, HRP II and HRP III in malaria parasite of diverse origin. *Parasitology.* **95(pt 2)**: 209-227.
- Makler M. T., Piper R. C. and Milhous W. K. (1998). Lactate dehydrogenase and diagnosis of malaria. *Parasitology Today.* **14(9)**: 376-377.
- Meier B., Dobeli H. and Certa U. (1992). Stage specific expression of adolase isoenzymes in the rodent malaria parasite *Plasmodium berghei*. *Molecular and Biochemical Parasitology.* **52(1)**: 15-27.
- World Health Organization (2008). World malaria report.
- World Health Organization (2005). Manual of basic techniques for a health laboratory, 2nd edition.
- Warhurst D. C. and Williams J. E. (1996). Laboratory diagnosis of malaria, ACP broadsheet no. 148. *J. Clin. Pathol.* **49**: 533-538.
- World Health Organization (1995). Management of uncomplicated malaria and the use of antimalarial drugs for the protection of travellers, Information consultation report, Geneva, WHO/MAL1075-98.
- Humar A., Ohrt C., Harrington M. A., Pillai D., and Kain C. A. (1997). ParaSight-F test compared with the polymerase chain reaction and microscopy for the diagnosis of *Plasmodium falciparum* malaria in travelers. *Am J Trop Med Hyg.* **56**: 44-48.
- Laferi H., Kandel K., and pichler H. (1997). False positive dipstick test for malaria. *N Engl J Med.* **337**: 1635-1636.
- Murray C. K. and Bennet J. W. (2009). Rapid diagnosis of malaria, Interdisciplinary Perspective on Infectious Diseases.

Table 1: Results of microscopic and ICT analysis

Technique	Positive for <i>P. f</i>	Positive for <i>P. v</i>	Positive for mix	Negative	Total
Microscopy	65	137	01	694	897
ICT	65	133	00	699	897

Table 2: 2x2 Results of microscopic and ICT analysis

ICT/ Microscopy	Positive	Negative	Total
Positive	187	11	198
Negative	16	683	699
Total	203	694	897




Fig. 1: Rapid Diagnostic Test Results

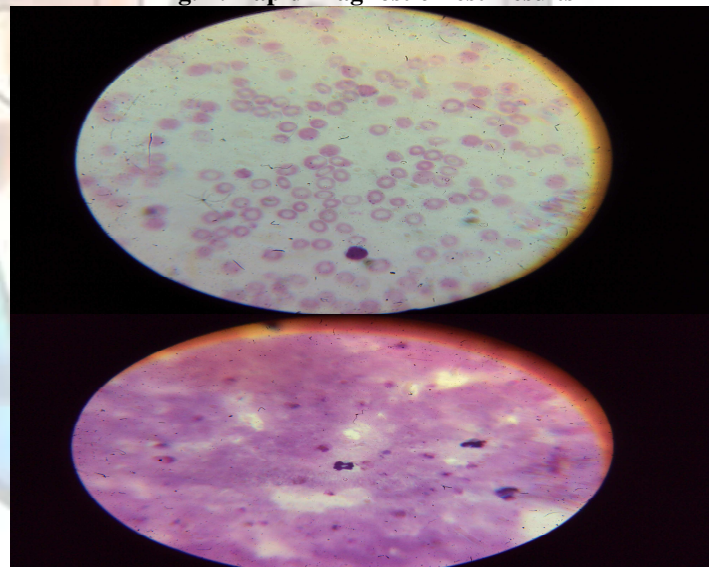


Fig. 2: Microscopic Observation of Malarial Parasites